



Medicine, like life, is full of surprises but common infections occur commonly



Here they come ~ a full set of experts!




"The next tourist to call me a leopard gets to be lunch"

NICD clinical hotline 080 021 2552

High index of suspicion for malaria. ASK TRAVEL HISTORY/RESIDENCE

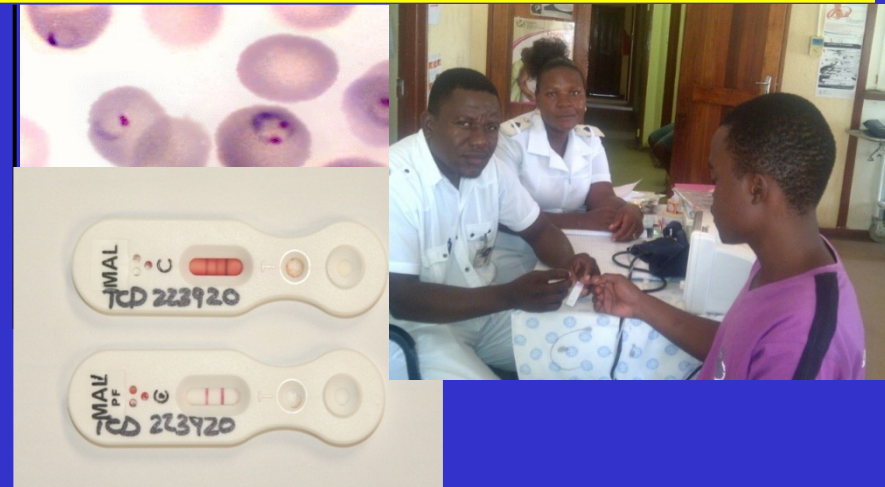Every patient with fever/ flu-like illness/acute progressive illness + travel to malaria area/residence in malaria area = MALARIA until disproved irrespective of consideration for COVID-19

- **COMPULSORY** - blood smear or RDT for malaria



Urgency
Get results
Repeat if negative

RX- Coartem uncomplicated
Artesunate severe

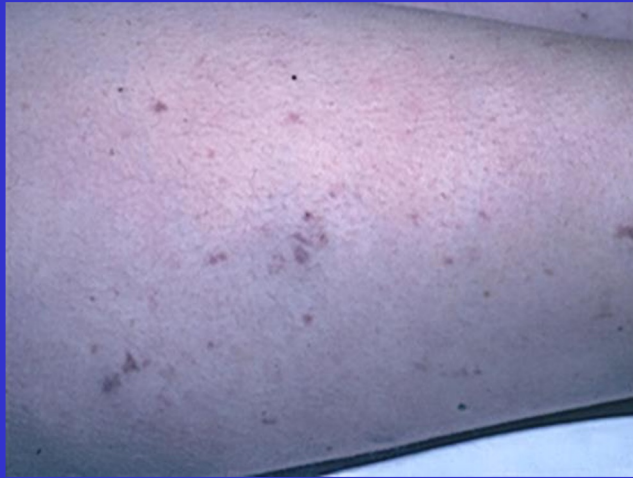

11 year old, resident in Northern Namibia – Cape Town holiday Xmas

- Fever- ? Flu, ? COVID
- Progressive jaundice - ? viral hepatitis
- Depressed level of consciousness- ? meningitis
- Admitted ICU

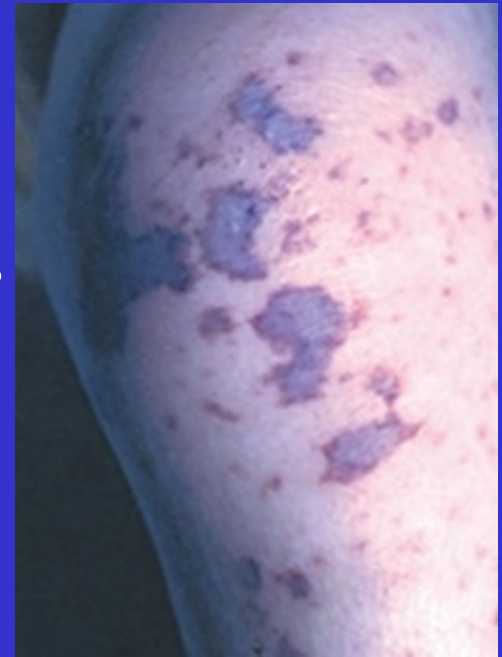
Healthy.....then within hours..... multiple visits to
health facility

Fever ...vomiting...then... lethargic..... then



1400hrs

1600hrs



WCC 2.4, platelets 90 000
CSF 15 neuts GRAM stain neg

Always consider meningococcal disease in acute/rapidly
progressive febrile illness in young patients

15 year old


0200hrs fever, headache, 'sore throat', FBC normal , anti-pyretic,
macrolide

1200 hrsvomitting, lethargic, abdominal pain, cat scan – normal,
anti-emetic

WCC 1 000, platelets 75 000

All the pieces of the puzzle must fit


- Where do you play, stay, school, travel
- Exposures- pets 'insects', plants, food, occupation of family members
- Outbreaks/endemic diseases in area
- Drugs, vaccines
- Immune status
- Dermatology
- Systemic symptoms and signs, progression of illness
- FBC and diff, LFTS, blood smear



•Laboratory



•Clinical



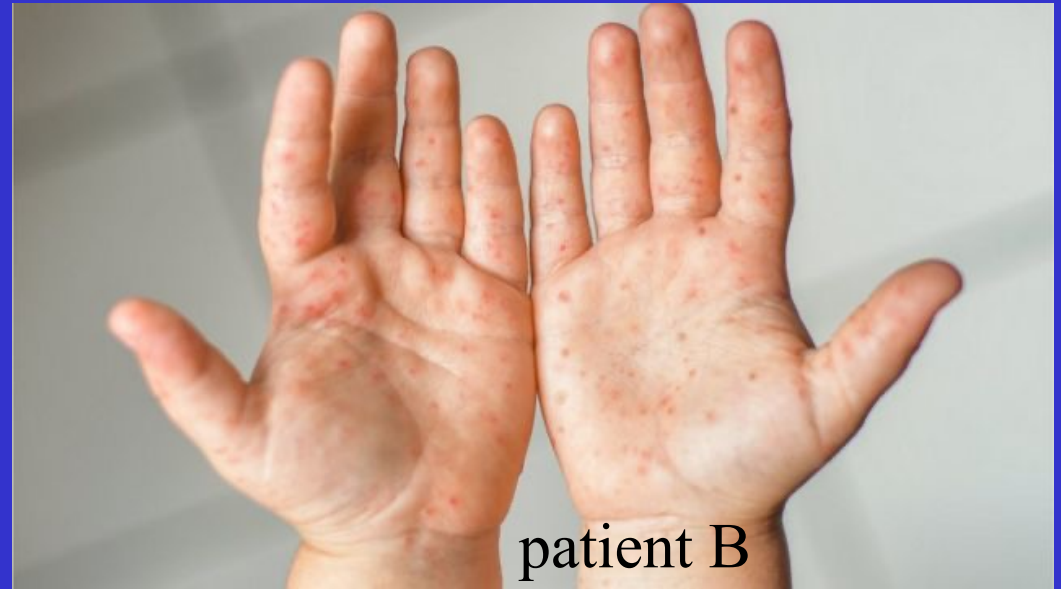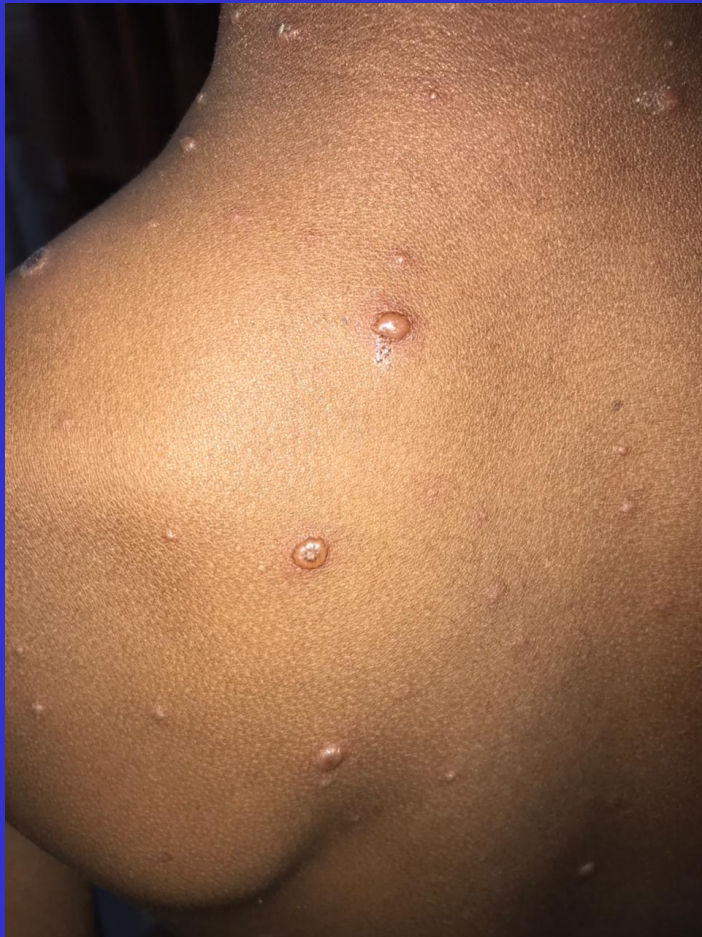•Epidemiology

Travelled to west Africa with mom,
previous 10 days in UK

- Fever, headache, myalgia, fatigue
- Malaria test positive
- Typhoid test positive
- COVID test positive

Request for monkey pox PCR.....

patient A



patient B



Monkey pox in endemic area

- Unexplained progressive multi-system illness- taxi malaria (MISC-C, other). Thrombocytopaenia common in malaria
- Progressive, fatal encephalitis (esp if normal CSF, normal CAT Scan (MRI –gray matter) think rabies
- **Current...**influenza , measles, polio (MOZ, Malawi), all vaccine-preventable infections, norovirus, typhoid
- **IPC** always, needlestick injury- confirm diagnosis in patient (not only Hep B, HIV)